

# Surgical Management of Gastroschisis

John H. T. Waldhausen,  
MD\*

Author Disclosure  
Dr Waldhausen did  
not disclose any  
financial relationships  
relevant to this  
article.

**Objectives** After completing this article, readers should be able to:

1. Explain the treatment options for gastroschisis and the basis on which treatment is chosen.
2. Describe the fluid needs of infants who have gastroschisis.
3. Explain methods of protecting the intestine and aiding in fluid and heat retention.
4. Delineate the causes of bowel ischemia at birth in newborns who have gastroschisis.
5. Outline the long-term outcome for infants who have gastroschisis.

## Introduction

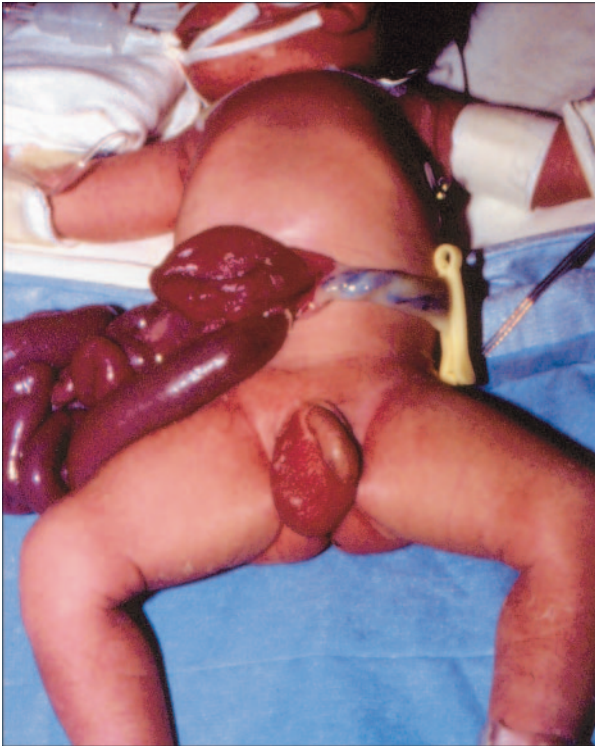Babies who have gastroschisis typically are born at 34 to 38 weeks' gestational age and undergo placement of a silo or primary abdominal closure within the first few hours after birth (Fig. 1). In general, affected infants do not have other life-threatening anomalies, and surgical management may be directed at repair of the intestinal herniation and abdominal wall defect. All affected infants have malrotation because the intestine failed to return to the abdominal cavity and become internally fixed. Approximately 10% have an intestinal atresia. Other anomalies are rare, in contrast to the infants who have omphalocele, in whom 50% have chromosomal with or without anatomic anomalies.

## Delivery And Postdelivery Care

The timing and method of delivery for infants who have gastroschisis remain somewhat controversial. One of the potential complications of the condition is the development of thickened bowel or a peel that makes safe primary closure difficult if not impossible (Fig. 2). An additional issue is shrinking of the fascial ring through which the bowel herniates during gestation, which can cause compression of the mesenteric vasculature, leading to bowel ischemia and potential loss of intestine. In rare instances, infants may be born with loss of a significant amount of intestine due to infarction from a closing fascial ring (Fig. 3). In an attempt to avoid such complications, some centers advocate serial ultrasonographic examinations of affected fetuses starting as early as 26 weeks' gestational age, looking for signs of intestinal compromise, such as increasing bowel wall thickness, increase in total bowel diameter, and lack of intestinal peristalsis. There is no general agreement on what measurement is clinically significant or what course of action is best once a specific measurement has been attained. Some authors suggest that a total bowel diameter of 2 cm is indicative of ischemia; others use a measurement of only 1 cm. Some centers advocate preterm delivery either by cesarean section or induced vaginal birth once specified measurements are attained; others believe in leaving the fetus in utero for as long as possible to avoid other potential complications of prematurity. The presumption is that earlier delivery based on serial measurements of the bowel may decrease the incidence of intestinal complications. Some nonrandomized studies indicate a shorter hospital course, earlier time to feeding, and decreased complications with a protocol that includes serial ultrasonographic examinations and early delivery. Other studies contradict these findings. Because no randomized, controlled trials have examined this question, no definitive data suggest the optimal timing of delivery, and various institutions report good outcome with and without early delivery.

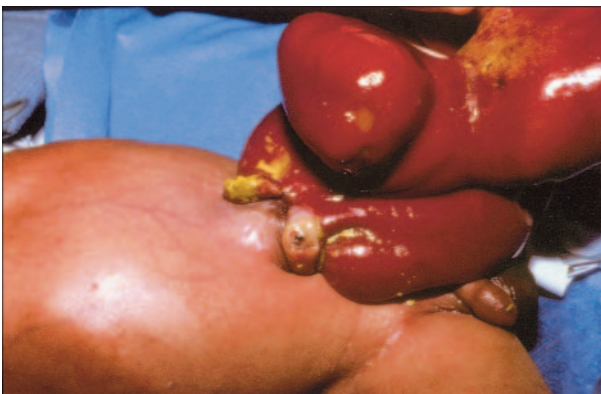The management of an infant who has gastroschisis prior to surgical repair is directed

\*Professor of Surgery, Children's Hospital and Regional Medical Center, University of Washington School of Medicine, Seattle, Wash.

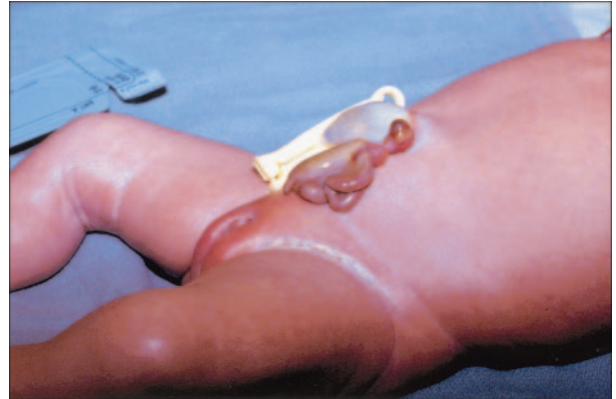

**Figure 1.** Typical infant who has gastroschisis. Note that the defect is to the right of the umbilicus.

toward fluid resuscitation, temperature management, and protection of the bowel. Because the intestine is herniated outside of the abdominal wall, a large quantity of serous fluid may be lost, and the bowel radiates substantial heat, which can lead rapidly to hypothermia. All affected infants must receive prompt, secure intravenous (IV) access through a peripheral IV line and be kept as warm as possible. Infants may need 90 to 200 mL/kg per day of total fluids to establish and maintain adequate



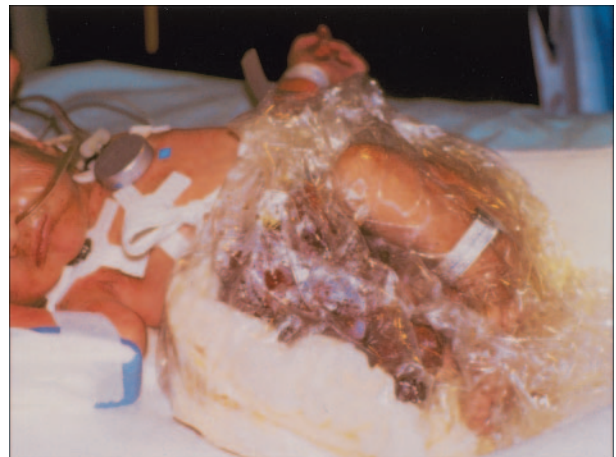**Figure 2.** Gastroschisis exhibiting thickened peel on the bowel prior to closure.



**Figure 3.** Loss of intestine due to closure of the fascial ring during gestation, resulting in an atresia and loss of most of the mid-gut.

urine output. Acidosis may be present because of hypovolemia. Bolus fluids using 5% albumin may be helpful because most affected infants also suffer hypoproteinemias.

Transport is best accomplished by placing the entire infant, to the level of the axilla, in a plastic bag (a bowel bag usually can be obtained from the operating room and works very well) (Fig. 4). The bag helps retain heat and moisture and protects the bowel. In almost all cases, the abdominal wall defect is to the right of the umbilicus. Therefore, babies should be placed with the right side down to cause as little tension as possible on the mesenteric vessels because they herniate outside of the abdomen. The intestine does not need to be supported on



**Figure 4.** Infant placed in a bowel bag for transport. Note the presence of a nasogastric tube. In this case, gauze is placed in the bag, but this approach requires a nonadherent dressing next to the bowel. The child should be transported with the right side down.

gauze, although if it is, a nonstick dressing must be placed on the gauze to help avoid bowel injury or the gauze may be placed outside of the bowel bag. It is best not to use moistened gauze in the bowel bag because even if moistened with warm saline, the saline rapidly cools and steals further heat from the infant.

Any meconium that passes is of little concern because it is sterile. All infants should receive antibiotics, typically ampicillin and gentamicin. A nasogastric tube must be placed to help decompress the bowel, particularly the stomach.

### Addressing the Ischemic Intestine

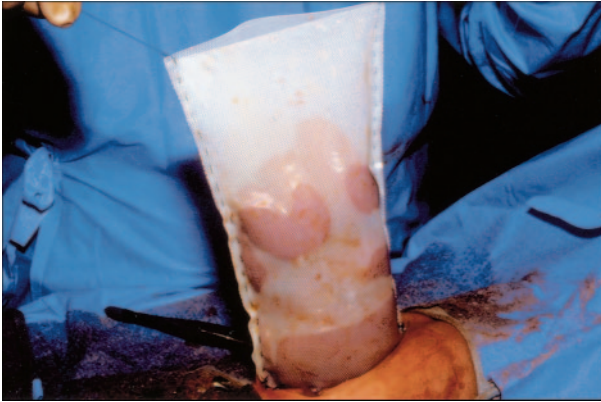
Careful attention must be paid to the intestine prior to surgical repair of the defect. During gestation, the fascial defect tends to close or at least become smaller. There is some evidence that this may account, in part, for the peel or thickened bowel seen in some infants who have gastroschisis. As the fascial defect closes, venous return is obstructed, leading to bowel edema and thickening. A tight fascial defect may become an acute issue at delivery and cause intestinal ischemia and eventual necrosis if not corrected. If the intestine appears ischemic at birth, there are three causes to consider. First, the fascial defect may be too small, causing vascular compromise. If this is true, the compromise is likely to be a chronic issue, and enlargement of the defect may not improve the situation, although acute enlargement of the defect may be attempted to help with perfusion. Such enlargement is undertaken best by incising the fascia superiorly, taking care to avoid the umbilical vein, which often can be accomplished without cutting skin and using a local anesthetic. The superior incision is preferred over an inferior incision because there are more structures that potentially may be cut inferiorly, such as both umbilical arteries and the urachus. Lateral incisions risk cutting rectus muscle, and if carried too far, the incision can injure the epigastric arteries.

The second cause of ischemic intestine is torsion of the bowel on the vascular pedicle during delivery. All infants who have gastroschisis have malrotation, and the vascular pedicle may be very narrow, thereby allowing torsion. In this circumstance, bowel detorsion results in relatively prompt recovery from the ischemic appearance. The third potential cause leading to intestinal ischemia is a distended stomach herniated out of the fascial defect. If the stomach becomes too distended, it may nearly occlude the hernia opening and compress the intestinal vasculature. A working nasogastric tube can resolve this problem, and its placement is essential as one of the initial steps in resuscitation.

### Surgical Treatment

Once initial resuscitation is accomplished, the child can be readied for surgery or transported to a surgical center as needed. There is considerable debate over the best means of treating the herniated bowel and timing the closure. Depending on the child, some surgeons advocate immediate closure, some prefer delayed closure, and some tailor the decision based on the child's condition. Further controversy surrounds whether the operation is best performed immediately in the delivery room or whether the child needs to go to the operating room and have the procedure performed under general anesthesia. One of the primary issues is that the abdominal cavity has not developed sufficiently to accommodate the intestine. Primary closure of the abdominal cavity may be successful in many cases, but abdominal compartment syndrome develops in a significant proportion of infants if primary closure is attempted. When this occurs, tight abdominal closure leads to abdominal hypertension that causes decreased renal venous outflow, leading to oliguria, as well as decreased cardiac venous return and intestinal ischemia. Canine models have shown that blood flow to all abdominal organs decreases as abdominal pressures rise from 0 to 20 mm Hg. This may be particularly detrimental to the infant who has gastroschisis because the bowel already may have compromised blood flow from a tight fascial defect at birth. If ischemia is uncorrected by release of the abdominal pressure, acidosis progresses, followed by intestinal necrosis and possibly death.

Although the physiology of abdominal compartment syndrome was not described until the 1990s, the poor clinical outcome caused by too tight a closure was readily apparent because few children survived the complication. The first successful report of primary closure was by Watkins in 1943. In this era, if primary closure could not be achieved, few children lived because there was no good method of covering the herniated intestine. Radical procedures to decrease the volume of intra-abdominal contents were attempted, including splenectomy, intestinal resection, and partial hepatectomy. Other surgeons used large skin flaps to cover the intestine. Although this provided coverage, it did nothing to increase the intrafascial abdominal volume. Attempts would be made later in life to place the bowel inside the abdomen, but the challenge of inadequate intra-abdominal space remained. Some surgeons described manually stretching the abdominal wall or used flaps from the anterior rectus sheath to gain additional intra-abdominal space. Techniques such as paralysis and prolonged ventilation and muscle



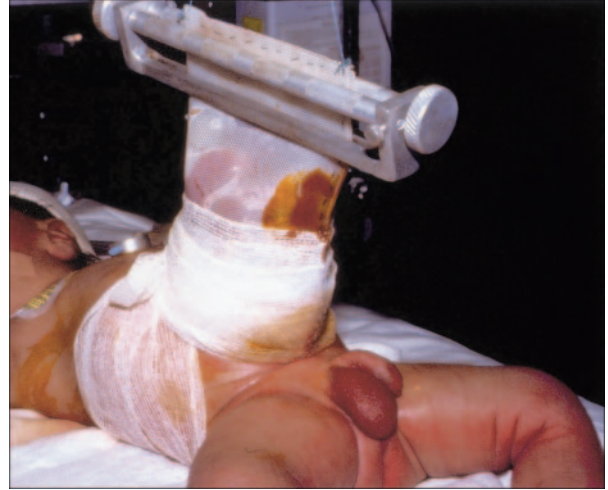**Figure 5.** Placement of a silo because of inability to perform primary fascial closure due to increased intra-abdominal pressure.

relaxation have been used to help achieve primary closure.

In 1967, Schuster described staged repair with visceroperitoneal disproportion. He used sheets of Teflon® mesh to form an external silo covered by skin and sequentially closed the silo until the fascial edges could be opposed. Polyethylene sheets were placed within the silo to prevent the intestine from adhering to the Teflon®. Schuster's technique provided temporary coverage and protection of the intestine and allowed gentle reduction of the contents into the abdomen. The skin had to be reopened periodically to reapproximate the mesh and achieve eventual closure. This technique has undergone many subsequent variations, but all approaches are aimed at coping with the infant in whom primary closure cannot be accomplished because of the development of abdominal compartment syndrome.

Two types of silos are in general use. The hand-made version created by the surgeon in the operating room requires an incision from the xiphoid to the pubic symphysis and suturing to the fascia (Fig. 5). Suturing makes the silo very secure, but because the silo material is silastic, there is no tissue in-growth. The sutures tend to dehiscence by about 14 days postsurgery, at which time the abdominal closure generally must be completed. The second type of silo is manufactured and has a spring-loaded ring that fits into the fascial defect. Usually no incision is needed unless the defect is small.

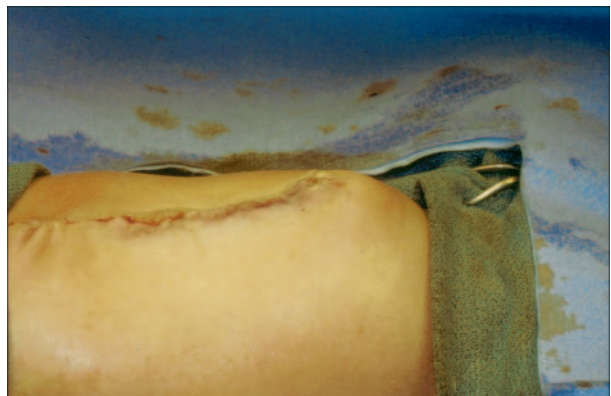The two types of silos generally are used in different situations, and use often depends on surgeon preference. The hand-sewn silo is used most often by surgeons when primary closure is attempted but not successful because of increased intra-abdominal pressure. The silo is placed and slowly reduced over 5 to 10 days until all of the



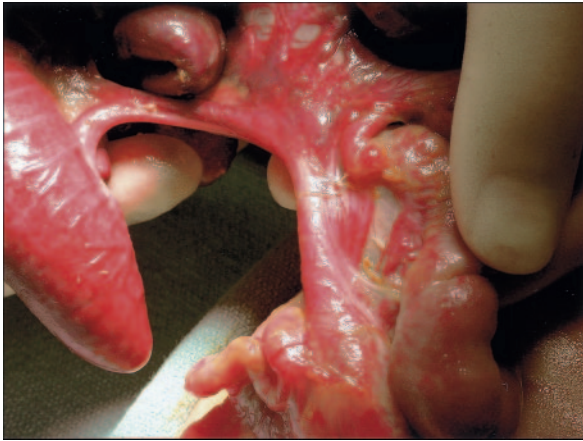
**Figure 6.** Silo with wringer clamp used to reduce the bowel slowly into the abdominal cavity. The clamp is rolled down over 5 to 10 days.

viscera are placed back into the abdomen (Fig. 6). The child then is returned to the operating room, and a fascial closure is accomplished, skin is closed, and an umbilicus is reconstructed (Fig. 7). The spring-loaded silo may be used in a variety of clinical situations. Some surgeons use this silo as the primary means of closure for all infants; some use it only if they believe primary closure is not immediately possible. One of the disadvantages of the spring-loaded silo is that mechanical downward pressure to help reduce the bowel may displace the spring-loaded ring out of the abdomen. This is not likely to occur with the sutured silo.

One of the reasons that any type of silo is useful is that the intestine often is edematous. This edema worsens the visceroperitoneal disproportion. Placing the bowel in the silo allows resolution of the edema and gentle reduc-



**Figure 7.** The bowel has been reduced fully, and the child has been returned to the operating room for final fascial closure.



**Figure 8.** Gastroschisis with intestinal atresia.

tion of the bowel into the abdomen following gradual abdominal distention. Some surgeons have used the preformed silos for edema resolution, believing that it may allow a greater incidence of primary closure. One of the advantages of the spring-loaded silo is that it may be placed at the bedside. Once the silo is in place, the bowel is protected and the child can be scheduled for elective closure of the abdomen rather than requiring an immediate trip to the operating room.

### Intestinal Atresia

One of the conditions associated with gastroschisis is intestinal atresia, which occurs in 10% of affected infants (Fig. 8). At times this anomaly may be apparent at the time of closure; for other infants, especially those who have a thickened peel on the intestine, the atresia may not become obvious until later, when there appears to be obstruction. Because ileus may be prolonged in affected infants, it may be difficult to discern initially whether prolonged ileus is due to atresia or if it is simply the normal postoperative course.

Once atresia is diagnosed, there are several approaches to handling the problem, which may depend, in part, on surgeon preference. Some surgeons advocate creation of an ostomy, with later reanastomosis once the fascia has been closed and increased intra-abdominal pressures have resolved. This may be appropriate in some cases, but it may leave the child with a proximal ostomy or, if a silo has been placed, increase the risk of infection and silo dehiscence. A generally safe course is to leave the atresia alone and keep the bowel decompressed with a nasogastric tube. The fascia may be closed primarily or in a delayed fashion with a silo. The child is returned to the operating room at a later date to establish intestinal continuity. We usually choose to reanastomose the

bowel approximately 4 weeks after fascial closure, which allows time for intestinal peel to resolve and for the anastomosis to be performed safely. The anastomosis may need to be performed earlier if the gastrointestinal tract cannot be decompressed adequately by nasogastric tube.

### Postoperative Issues

Once the abdomen is closed, several issues require close attention postoperatively. In the immediate postoperative period, infants who have gastroschisis may appear to be edematous, especially in the lower extremities. This is likely due to increased abdominal pressure and although concerning, generally resolves with time. The abdomen may appear erythematous for several reasons. Often surgeons manually stretch the abdomen to help reduce the intestine. Such stretching may cause significant erythema that resolves over time. A tight closure also may cause some erythema, although ischemia to the intestine or infection also should be considered. Frequently it is difficult to differentiate erythema due to infection from erythema due to manual stretching, making administration of antibiotics prudent. Intestinal ischemia must be diagnosed because it may be a life-threatening issue. The intestine may become ischemic for two reasons: the abdominal closure may be too tight, leading to vascular compromise, or the intestine may have been torsed on a narrow vascular pedicle during reduction, causing ischemia. Frequently, infants have some degree of metabolic acidosis immediately postoperatively that may be due to hypovolemia and resolves with appropriate fluid boluses. If acidosis fails to resolve despite fluid administration, visceral ischemia should be considered, and surgical re-exploration undertaken if the issue cannot be resolved by other means.

Fluid requirements are increased both pre- and postoperatively in the infant who has gastroschisis compared with other infants. After repair, fluids may need to be administered at a rate of 140 to 150 mL/kg per day. It is important to administer fluids judiciously because there is evidence that overhydration may lengthen hospital stay and delay return to enteral feeding. Some of the clinical findings typically used to determine adequate volume status may be compromised in the infant postoperatively. Urine output may be decreased despite adequate volume status because the abdomen is somewhat tight and renal perfusion is altered. It may be necessary to accept urine output less than the usual 2 mL/kg per hour initially. Capillary refill in the lower extremities also may be sluggish due to venous hypertension caused by a tight abdominal closure. Other examinations, including chest

film looking at the cardiac silhouette or cardiac echocardiography to determine left ventricular filling volume, may be needed to judge the volume status of the child adequately.

Serum protein/albumin concentrations are usually low, which may increase third spacing and the required volume of fluids. Protein should be measured and replacement with 25% albumin provided as needed. Antibiotics should be administered for a brief time postoperatively if a primary closure is achieved but should continue if a silo is used until the prosthesis is removed. Infants usually are ventilated postoperatively because of increased abdominal pressure and decreased compliance. Infants who have a silo in place may be extubated prior to silo removal if desired, and the silo can be reduced gradually at the bedside, even in an extubated child. The silo is reduced daily while observing the infant's respiratory rate and degree of comfort. When the child becomes uncomfortable or the respiratory rate increases, the silo has been reduced enough for that day. Although this is a purely subjective method of silo reduction, experience has shown it to be successful. Some advocate measurement of intragastric or bladder pressures as a more objective guide for reducing the visceral contents. If the child is still intubated, ventilation pressures can be monitored to judge the extent of daily reduction.

Feeding is delayed in almost all infants who have gastroschisis whether the child underwent primary closure or delayed closure with a silo. Ileus usually lasts a minimum of 10 days and may extend for weeks to months. Grosfeld and colleagues reported a mean duration of 26 days. The intestine is physiologically, if not anatomically, short compared with that of a healthy infant. The infants require central venous access and total parenteral nutrition (TPN) until enteral feeding can be started. TPN should be started early in the postoperative period because prolonged ileus should be expected. Prolonged TPN can be complicated by catheter sepsis and hepatopathy. Measures that may prevent these complications, such as use of choleretics and TPN cycling, can be considered. Once enteral feedings are begun, they frequently must be advanced slowly. Although the infant may desire and be able to take a bottle or nurse from the breast, the intestine may not be able to handle a large volume. Frequently, the infants require drip-feeding, with slow advancements of 1 to 2 mL/d or less. Human milk or colostrum, if available, may be used; if not available, a predigested or elemental formula is advisable. Feedings may be advanced relatively rapidly; in some infants, 2 to 3 weeks are required to reach full enteral

feeding, and in others, months are required to achieve the transition.

Several different complications may be experienced postoperatively. Immediate complications include volvulus and infection, as already discussed. Infants treated with a sutured silo may experience silo dehiscence if reduction and closure has not been accomplished by approximately 10 to 14 days after placement. This represents a potentially difficult problem if fascial closure cannot be achieved. The silo generally cannot be replaced because the dehiscence probably is due to abscess formation at the suture sites. If fascial closure cannot be achieved, several techniques have been described to allow coverage of the bowel. The primary issue is to protect the bowel and avoid fistula formation. The development of a fistula in the absence of fascial closure may be a life-threatening complication.

Some complications may be delayed in presentation. Because affected infants have malrotation, they are always at some risk of mid-gut volvulus. This should be considered if the child presents with bilious vomiting. In general, adhesions formed after reduction of the bowel prevent this from being an issue, but most series of infants presenting with mid-gut volvulus include children who have a history of gastroschisis. Feeding intolerance is common because of the physiologically short bowel. As mentioned previously, feeding advancement often must proceed slowly, and infants need to be followed for signs of malabsorption. Evidence of malabsorption may require a change in formula, a decreased caloric concentration of formula, or a slower feeding advancement. Malabsorption may present as a distended abdomen, failure to gain adequate weight despite the appearance of adequate caloric intake, or guaiac-positive stools. Infants may have problems with bacterial overgrowth in a distended, poorly motile loop of bowel. Although these problems always should be considered, such symptoms may signal sepsis (commonly due to a line infection) or necrotizing enterocolitis (NEC). A septic evaluation, including abdominal films, is essential in these situations. NEC often occurs several weeks after abdominal closure and is a major cause of mortality (20% of deaths in some series). It is diagnosed by the presence of pneumatosis on a plain abdominal film and should be treated with bowel rest (NPO), nasogastric suction, and broad-spectrum antibiotics for approximately 10 days. Operative intervention is rarely necessary.

Abdominal closure, in most cases, causes some increase in abdominal pressure and can lead to problems with gastroesophageal reflux (GER) or hernia development. GER may be subtle and not present with overt

vomiting. The child may be only irritable from occult reflux, and administration of a histamine<sub>2</sub> blocker or proton pump inhibitor may resolve the symptoms. Occasionally, a fundoplication is needed, although most infants can be managed nonoperatively. Inguinal hernias need to be repaired when the child is stable and abdominal pressure has decreased. There is also a reported increased incidence of cryptorchidism in infants who have gastroschisis, which may have some bearing on the timing of inguinal hernia repair. Ventral hernias may occur if a sutured silo was used because the fascia may be somewhat attenuated with a tight closure.

The overall survival of children who have gastroschisis exceeds 95%. The first several months can be difficult for both the child and the parents because the infant is confined to the hospital undergoing surgical treatment and generally slow advancement of feedings. It may be difficult for the parents to understand why feeding advancement takes so long in some cases. There are reports of infants who have gastroschisis being on the lower end of weight growth curves, but it is not clear if this is a result of the gastroschisis per se or if the finding is related to prematurity, low birthweight, and other nongastroin-

testinal issues. Communication with the parents is essential, reassuring them that the long-term outcome for most children is excellent and that most subsequently lead normal lives.

### Suggested Reading

- Allen RG, Wrenn EL Jr. Silon as a sac in the treatment of omphalocele and gastroschisis. *J Pediatr Surg.* 1969;4:8
- Fonkalsrud EW, Smith MD, Shaw KS, et al. Selective management of gastroschisis according to the degree of visceroperitoneal disproportion. *Ann Surg.* 1993;218:742-747
- Grosfeld JL, Dawes L, Weber TR. Congenital abdominal wall defects: current management and survival. *Surg Clin North Am.* 1981;61:1037-1099
- Kidd JN, Jackson JR, Smith SD, et al. Evolution of staged versus primary closure of gastroschisis. *Ann Surg.* 2003;237:759-765
- Koivusalo A, Lindahl H, Riintala RJ. Morbidity and quality of life in adult patients with a congenital abdominal wall defect: a questionnaire survey. *J Pediatr Surg.* 2002;37:1594-1601
- Minkes RK, Langer JC, Mazziotti MV, et al. Routine insertion of a silastic spring-loaded silo for infants with gastroschisis. *J Pediatr Surg.* 2000;35:843-846
- Molik KA, Gingalewski CA, West KW, et al. Gastroschisis: a plea for risk categorization. *J Pediatr Surg.* 2001;36:51-55
- Schuster SR. A new method for the staged repair of large omphaloceles. *Surg Gynecol Obstet.* 1967;125:837-845

## NeoReviews Quiz

4. A male infant, born at 34 weeks of estimated gestational age following spontaneous vaginal delivery, has gastroschisis. The infant is being readied for transfer to a tertiary care facility. Of the following, one of the *first* steps in pretransport stabilization of this infant is to:
  - A. Administer 5% albumin for correction of hypoproteinemia.
  - B. Administer sodium bicarbonate buffer to correct acidemia.
  - C. Apply moistened gauze to the exposed bowel.
  - D. Cover the infant in a plastic bag to the level of the axilla.
  - E. Provide intravenous fluids at a rate of 70 mL/kg per day.
  
5. One of the methods of surgical closure of gastroschisis is the use of a sutured silo. Placement of the sutured silo typically requires an incision from the xiphoid process to the pubic symphysis and suturing of the silo to the fascia. The silo then is reduced sequentially until primary abdominal closure is attempted. The risk of suture dehiscence makes it critical that the primary abdominal closure be attempted in a timely fashion. Of the following, the *latest* period after birth for accomplishing primary abdominal closure of gastroschisis to avoid the risk of suture dehiscence is:
  - A. 7 days.
  - B. 14 days.
  - C. 21 days.
  - D. 28 days.
  - E. 35 days.
  
6. An infant who has gastroschisis is at risk for several early and late complications following surgical closure. Of the following, the late complication after surgical closure of gastroschisis *most* associated with mortality is:
  - A. Feeding intolerance.
  - B. Gastroesophageal reflux.
  - C. Mid-gut volvulus.
  - D. Necrotizing enterocolitis.
  - E. Sepsis.